

# New Data on the Involvement of Ectodermal Epithelium in Extrathymic Differentiation of Human T-Lymphocytes

Z. S. Khlystova, I. I. Kalinina, and S. P. Shmeleva

Translated from *Byulleten' Eksperimental'noi Biologii i Meditsiny*, Vol. 138, No. 8, pp. 221-224, August, 2004  
Original article submitted January 21, 2004

---

Thymalin accumulates only in young cells of the skin ectodermal epithelium and mucosa of the anterior portions of the digestive and respiratory systems. After appearance of keratin the cells no longer accumulate thymalin. Similarly as in the thymus, thymalin content in the ectodermal epithelium of the organs is subjected to age-associated involution.

---

**Key Words:** *epidermis; lymphocyte; human ontogenesis*

The key role of the endocrine and lymphocytopoietic functions of the thymus in T-lymphocyte differentiation and status of the entire immune system is well known. Further deciphering of intricate histophysiology of all its components is required. It remains unclear whether both functions of the thymus appear simultaneously, what attracts lymphocytes into the thymus, why the epithelial tissue serves as the base for the thymus, but not for other organs of the immune system, and which are the compensatory processes in the immune system in case of the thymus involvement (and if they are possible, at the expense of which tissues they are realized). The epithelial microenvironment (naturally capable of secretion) of T-lymphocytes plays an important role in their differentiation. The thymic epithelial cells produce hormones providing T-lymphocyte differentiation; these hormones are used in foreign clinics as immunomodulators for immunodeficiency correction with good results [13]. Immunomodulators tactivin [1] and thymalin [2] are created and used in Russia. Thymalin is a T-cell differentiation inductor, normalizing the immunological parameters in immunodeficiency, and is an effective drug for the correction of secondary immunodeficiency [6]. Thymalin is a complex of 1000-5000 D poly-

peptides (according to gel chromatography on Sephadex G25 and G50). It differs from other known hormones of the thymus and has no homologous amino acid sequences common with them [3]. Antithymalin antiserum to this Russian preparation was prepared; using this serum, it is now possible to detect thymalin-positive cells in a histological preparation. Using this antiserum we detected cells capable of accumulating thymalin in human organs and obtained additional data on the possibility of extrathymic differentiation of T-lymphocytes in the absence of the immediate thymic microenvironment.

Differentiation of T-lymphocytes is closely associated with the secretory epithelium of the thymus, and therefore it was necessary to clear out whether the stratified epithelium of other organs, developing from the same embryonal primordium, retained the capacity to accumulate thymic factor (thymalin) capable of initiating T-lymphocyte differentiation. If so, extrathymic differentiation of T-lymphocytes can be realized in the absence of the thymic microenvironment, which helps to better understand the compensatory defense processes.

We measured thymalin initiating T-lymphocyte differentiation in the stratified epithelium of organs developing (similarly as thymus epithelium) from the ectoderm: in the skin epidermis, mucosal epithelium of the anterior compartments of the digestive and re-

---

Laboratory of Embryonal Histogenesis, Institute of Human Morphology, Russian Academy of Medical Sciences, Moscow

spiratory systems (human organs in which fetal defense mechanisms appear in response to penetration of fetal and maternal antigens).

## MATERIALS AND METHODS

In order to study the embryogenesis of human fetal immune system, more than 600 fetuses of different age groups were examined at Laboratory of Embryogenesis, Institute of Human Morphology [8]. Of these, 40 fetuses aging 6-30 weeks obtained from healthy women as a result of induced abortions for various causes and organs of 3 dead adults collected at autopsy were used for detection of thymalin in tissues. Russian antithymalin serum was kindly provided by Professor V. Kh. Khavinson. Cryostat sections (4-5  $\mu$ ) were prepared from fragments of the thymus, skin, lung, oral organs, esophagus, and intestine (control) frozen in liquid nitrogen; the sections were dried, fixed in acetone (5°C), and washed in cold buffered saline (BS; pH 7.4) for 15 min. The sections were then incubated with rabbit antithymalin antiserum for 40 min, washed 3 times (15 min each time) in cold BS, and incubated for 20 min with FITC-labeled asinine serum to rabbit globulins. Antithymalin serum was used in the indirect agglutination test (1:64 titer). In order to minimize the specific adsorption of proteins, the conjugates were treated with human liver powder before incubation with the sections. Control sections were treated with intact serum or BS and examined under a LUMAM-P-3 fluorescent microscope.

## RESULTS

The study was carried out in several stages. The thymus is the organ of the endocrine and immune systems, and hence, the first task was to clear out the order of appearance of these functions in the thymus. It was found that the endocrine function appeared first [11]. Thymalin, the product of ectodermal epithelium of the organ stroma, functions here as an important factor in T-lymphocyte differentiation. Thymalin is present in the epithelial cell cytoplasm and intercellular spaces of the thymus during weeks 4-5 of intrauterine development. The first lymphocytes are already detected in the liver, though there is no thymalin in hepatocytes. Presumably, during this early period of embryogenesis the effect of thymic thymalin on the only hemopoietic organ is distant, ensuring the appearance of up to 1% T-lymphocytes (CD2<sup>+</sup> cells) in it. The endocrine and lymphopoietic functions are united in the thymus during embryogenesis weeks 7.5-8 (Fig. 1).

At stage II we investigated the possibility of thymalin secretion outside the thymus. Thymalin was

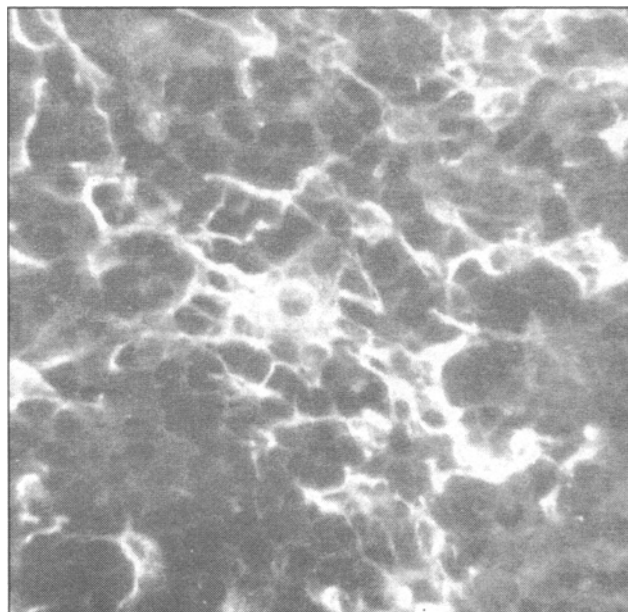


Fig. 1. Thymus of human fetus (23 weeks). Thymalin-positive cells,  $\times 800$ . Here and in Figs. 2, 3: indirect Coons' method.

detected in the ectodermal epithelium in some related tissues, primarily in the skin epidermis. It is known to contain T-lymphocytes, Langerhans cells as dendritic macrophages of the skin, participating in immunological reactions [4]. They accumulate antigen and stimulate T-helpers. Some authors [7] admit the possibility of lymphocyte migration into the skin and differentiation of T-cells in it, which explains the formation of T-cell lymphomas under certain conditions. Other authors [14] reported the absence of thymalin and thymosin in the skin. The effect of Russian thymalin on the skin was never studied [3]. Using anti-thymalin serum, we detected some clear-cut regula-

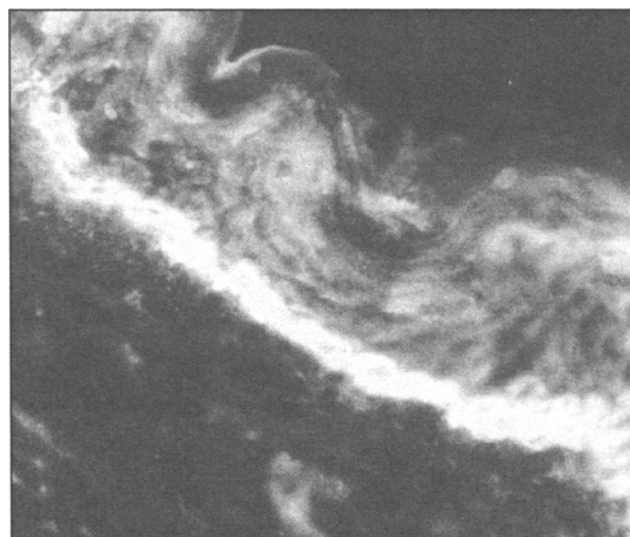
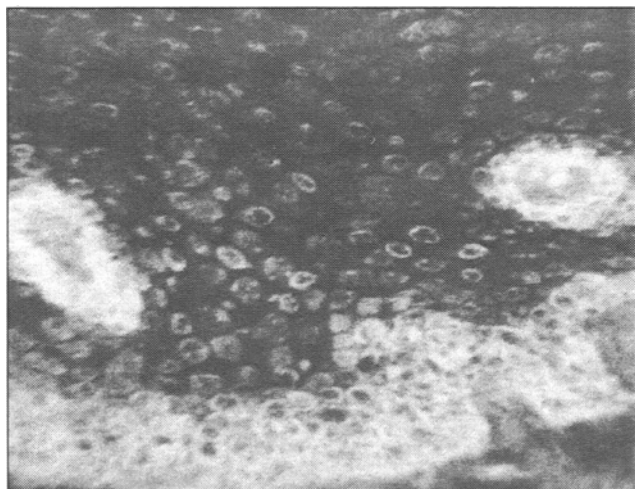


Fig. 2. Skin epidermis of 40-year-old man. Thymalin-positive cells in basal layers,  $\times 250$ .



**Fig. 3.** Esophageal epithelium from 40-year-old man. Thymalin-positive cells,  $\times 250$ .

rities. Thymalin is detected in the skin epidermis of various sites of fetal body and accumulates only in young basal keratinocytes. In a 10-week fetus the epidermis consists of solely young cells filled with thymalin [10]. With thickening of the epidermis, thymalin is no longer detected in the cells of the upper layers of keratin-containing plast [9]. Similarly as in fetal skin, it is present in only young basal cells. In a 40-year-old adult (Fig. 2) thymalin-containing cells form several layers. Their bulk changes with aging. By the age of 70 years the layer of thymalin-positive cells is thinned and is lacking at some sites, that is, the content of the thymic factor in the skin decreases with age. It is known that the thymus also undergoes involution with age, but it does not disappear completely. The epithelium of organs of the anterior compartments of the digestive and respiratory systems, similarly as human fetal skin, very early comes in contact with the complex amniotic fluid, and T-lymphocytes (CD2<sup>+</sup> cells) are detected in fetal epithelium as early as during weeks 10-13 of development. By 19 weeks the content of T-lymphocytes in the oral tissues reaches 60% of their total content and this percentage does not change until birth. By 17 weeks the oral epithelium undergoes reticulation, similarly as in the thymus, and is infiltrated with lymphocytes [8].

Thymalin is detected in human fetus in the stratified epithelium covering the skin type mucosa. Similarly to the skin, it is present in the youngest cells of the stratified epithelium from the oral cavity to the esophagus. Thymalin-positive cells are clearly seen in the lingual and esophageal mucosa (Fig. 3). No thymalin was detected in the single-layer epithelium of entodermal origin in the same fetuses.

The search for thymalin in the respiratory organs was initiated by publications, whose authors hypothesized that the lung can be considered as a peripheral

component of the immune system [5] possessing endocrine functions. These hypotheses were confirmed by the data indicating that human fetal (8-15 weeks) lungs contained cells with T-lymphocyte markers: mature (CD3<sup>+</sup>), with receptors to sheep erythrocytes (CD2<sup>+</sup>), CD4<sup>+</sup>, CD8<sup>+</sup>, etc. In a fetus aged 8-15 weeks thymalin was detected in epithelial cells of the airways (trachea and large bronchi) [12]. Cells with thymalin were situated as separate elements in the developing lung parenchyma in the respiratory part of the organ. These cells were described [3] as incretory, with heterogeneous functions, releasing biogenic amines and polypeptides.

Hence, thymalin-positive cells in human fetus appear in organs early exposed to unfavorable maternal and fetal antigens emerging in embryogenesis. The thymus is the only organ of the immune system based on epithelial tissue. The capacity to accumulate the thymic factor thymalin is common for the epithelium of the studied organs and thymic epithelium. Thymalin is accumulated only in young cells of the basal area of the epithelium. Fetal organs contain mature T-lymphocytes of different subpopulations at the early stages of embryogenesis.

Our findings extend our knowledge on the peripheral organs of human immunogenesis system and indicate that the skin and anterior compartments of the digestive and respiratory systems should be referred to this system. They should be regarded as components of the immune system with local defense functions at a large area of human body. But they should not be separated from the entire immunogenesis system, as they exist in such a form during the intrauterine period and after birth and undergo age-associated involution parallel with involution of the thymus.

## REFERENCES

1. V. Ya. Arion, *Itogi Nauki i Tekhniki*, Ser. Immunol., 10, 45-46 (1982).
2. V. G. Morozov and V. Kh. Khavinson, *Dokl. Akad. Nauk SSSR*, 240, 1004-1007 (1978).
3. V. G. Morozov, V. Kh. Khavinson, and V. V. Malinin, *Peptide Thymomimetics* [in Russian], St. Petersburg (2000).
4. M. V. Pashchenko and B. V. Pinegin, *Immunologiya*, No. 4, 7-16 (2001).
5. L. K. Romanova, *Cellular Biology of the Lungs in Health and Disease* [in Russian], Moscow (2000), pp. 253-269.
6. V. S. Smirnov and V. G. Morozov, *Immunologiya*, No. 4, 53-55 (1991).
7. M. Sokolov, *Clinical Immunology* [in Russian], Moscow (1998), pp. 209-212.
8. Z. S. Khlystova, *Development of Immunogenesis System in Human Fetus* [in Russian], Moscow (1987).
9. Z. S. Khlystova, I. I. Kalinina, O. P. Ryabchikov, and V. Kh. Khavinson, *Byull. Eksp. Biol. Med.*, 133, No. 6, 713-715 (2002).

10. Z. S. Khlystova, I. I. Kalinina, and V. Kh. Khavinson, *Ibid.*, No. 2, 231-233.
  11. Z. S. Khlystova, I. I. Kalinina, S. P. Shmeleva, and O. P. Ryabchikov, *Ibid.*, **130**, No. 10, 453-456 (2000).
  12. Z. S. Khlystova, I. I. Kalinina, and S. P. Shmeleva, *Ibid.*, **135**, No. 6, 703-705 (2003).
  13. A. L. Goldstein, T. L. Low, M. McAdoo, *et al.*, *Proc. Natl. Acad. Sci. USA*, **74**, 725-729 (1977).
  14. J. F. Nicolas, C. Auger, M. Dardenne, *et al.*, *Thymus*, **12**, 187-201 (1988-1989).
-